

## Fine Needle Aspiration Cytology of Palpable Breast Lumps with Histologic Correlation: A Two-Year Review

Parakh Priyanka<sup>1</sup>, Mathur Asha<sup>2</sup>

<sup>1</sup>Senior Resident, Department of Pathology, RNT Medical College, Udaipur, Rajasthan 313001, India. <sup>2</sup>Senior Professor, Department of Pathology, Dr. SN Medical College, Jodhpur, Rajasthan 342003, India.

### Abstract

**Aims:** To determine the histopathologic correlation of breast FNAC.

**Settings and Design:** This is a two-year prospective study of breast lumps seen at Department of Pathology, Dr. S.N. Medical College, Jodhpur (Rajasthan) between June 2011 and June 2013.

**Methods and Material:** A total of 526 FNAC cases were evaluated. Histologic follow up was available for 173 FNAC samples.

**Statistical analysis used:** The cytological diagnoses were categorised into one of five diagnostic categories in accordance with the National Health Services Breast Screening Programme of Britain classification (C1, C2, C3, C4, & C5). Then cytological findings were correlated with histological findings and accuracy was assessed by calculating sensitivity, specificity, positive likelihood ratio, negative likelihood ratio, predictive value, false negative, false positive rates and accuracy.

**Results:** Between June 2011 to June 2013 a total of approximately 526 FNAC breast cases were evaluated. Histologic follow up was available for 173 FNAC samples. Amongst all the cases (526) reported in cytology, maximum cases i.e., 417 (79.28%) cases had C2 lesions. Out of 526 FNAC cases, 173 were correlated in histology. So, in total there were 3 false positive cases and 4 false negative cases in this study. Results calculated were: sensitivity= 89.47%, specificity= 97.78%, positive predictive value= 91.89%, negative predictive value= 97.06% and accuracy= 95.95%

**Conclusions:** A high sensitivity and a high positive predictive value proved that a positive FNAC in the breast means a definite diagnosis of the concerned pathology when compared with the final histology report. The high specificity and a high negative predictive value for malignancy illustrated the high accuracy of FNAC in the diagnosis of malignancy in the breast.

**Keywords:** FNAC; Histopathology; Correlation; Sensitivity; Accuracy.

### Corresponding Author:

Parakh Priyanka, Senior Resident,  
Department of Pathology, RNT Medical  
College, Udaipur, Rajasthan 313001, Indi

E-mail: Priyanka\_parakh@hotmail.com

Received on 20.12.2018,

Accepted on 16.01.2019

### How to cite this article:

Parakh Priyanka & Mathur Asha. Fine Needle Aspiration Cytology of Palpable Breast Lumps with Histologic Correlation: A Two-Year Review. Indian J Pathol Res Pract. 2019;8(1):83-90.

## Introduction

There is a wide variety of breast pathology. Breast lump is the most common presentation in most of the breast diseases. Most of the breast lesions are benign [1]. However, Breast carcinoma is the most common malignant neoplasm and the leading cause of death from cancer in women, with more than 1 million cases occurring worldwide annually [2]. In India, breast cancer is second most common cancer in the women [3]. It is difficult to assess nature of lump by clinical assessment only.

Open surgical biopsy is the gold standard for diagnosis of palpable breast lump, but in recent years two types of minimally invasive breast biopsy techniques, core needle biopsy (CNB) and fine needle aspiration cytology (FNAC), are used for the diagnostic evaluation of palpable breast lesions. The procedure of core biopsy (CB) or tru cut biopsy is more cumbersome, expensive and time consuming as compared to FNA procedure [4,5,6]. Therefore, several studies advocate Triple test consisting of FNAC, physical examination and Mammography to be 100% accurate for diagnosis of palpable breast lesions [7].

The Fine Needle Aspiration (FNA) was first introduced by the Martin and Ellis in 1930 [8]. It is a highly sensitive, easy to perform and cost-effective investigation that can be carried out at outpatient department [9,10]. Different studies show that the FNAC has the sensitivity range from 80 to 98% and the specificity range of more than 99-100% [11]. However, the diagnosis by FNAC may be presumptive in some cases and the final diagnosis in such cases is achieved by histopathological examination of the tissue removed surgically [12]. To enhance communication within a multidisciplinary team and for comparing results from other centres, the National Health Services Breast Screening Programme of Britain has classified FNAC reports into 5 categories [13]. The categories and their numerical codes are: Inadequate (C1), Benign (C2), Atypical/indeterminate (C3), Suspicious of malignancy (C4), and Malignant (C5).

We aim to publish two-year experience of our institute determining the correlation between the results of breast FNAC and corresponding tissue biopsy and consequently determine the accuracy of subclassification of FNAC reporting.

## Material and Methods

This is a two-year prospective study of all the

patients with palpable breast lump presenting at the general surgery OPD of Dr. Sampurnanand Medical College, Jodhpur (Rajasthan). Permission was taken from the ethical committee of the institute before commencement of the study. Non-probability convenient sampling technique was used to collect samples.

FNA was done using a 22-gauge needle and 20 ml disposable syringe and smears were stained with Giemsa stain.

The cytological diagnoses were then categorised into one of five diagnostic categories in accordance with the National Health Services Breast Screening Programme of Britain classification [13].

- (C1) Inadequate
- (C2) Benign
- (C3) Atypical, probably benign
- (C4) Suspicious of malignancy
- (C5) Positive for malignancy.

The inadequate lesions were advised a repeat FNAC.

In the calculations, groups C4 & C5 were considered malignant and groups C2 & C3 as benign.

The cytological entities were further subclassified into definite entities.

Data was recorded regarding the age of the patient, site of involvement, size of the lesion, cytological diagnosis.

The data were entered into a database and statistical analyses carried out. The results were presented in frequency tables and cross tabulations.

Cytological findings were correlated with histological findings and accuracy of cytological diagnosis was assessed by calculating sensitivity, specificity, positive likelihood ratio, negative likelihood ratio, predictive value, false negative, false positive rates and accuracy.

## Results

Between June 2011 to June 2013 a total of 500 patients presenting with breast lump were evaluated. There were 40 (8%) male patients and 460 (92%) female patients. Male to female ratio in the study was 1:11.5. Out of these 26 patients had bilateral breast lump. So, total 526 FNAC cases from 500 patients were evaluated. Histologic follow up was available for 173 FNAC samples giving a biopsy rate of 32.89%. Right breast (54.4%)

was more commonly involved than the left breast (40.29%) and bilateral breast (5.32%).

The patients were from 12-90 years of age with a mean of 36 years. Out of all cases, maximum no. of cases was in 21-30 years of age group (146=29.2%).

Amongst all the cases (526) reported in cytology, maximum cases i.e., 417 (79.28%) cases had C2 lesions, followed by 84 (15.97%) cases reported as C5 lesions, 11 (2.09%) cases were reported as C1 and 8 (1.52%) and 6 (1.14%) cases were reported as C3 and C4 lesions respectively. (Fig. 1)

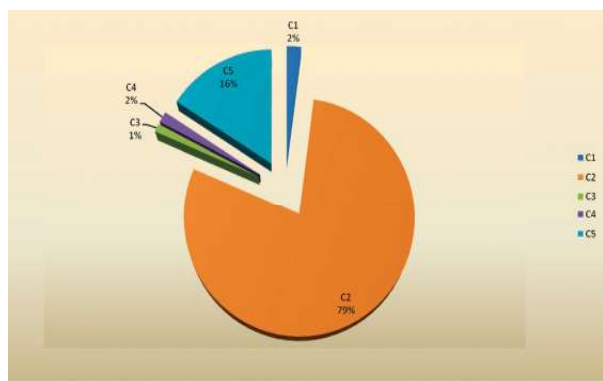


Fig. 1: Cases distribution according to NHSBSP cytological categories

In benign proliferative breast lesions, we were very conscious about over-diagnosis, therefore our reporting style was as “smear negative for malignant lesions”, and for further analysis we advised an excision biopsy. For definite diagnosis, our reports were limited to Fibroadenoma, fibrocystic change disease, benign proliferative disease, and Phyllodes tumours. For uncertain categories we only reported “benign proliferative lesions”.

In males, Gynecomastia was the most common (36=82%) cytological diagnosis, followed by acute mastitis and benign proliferative disease. There was only one case reported as malignant breast mass and inadequate respectively. (Fig. 2)

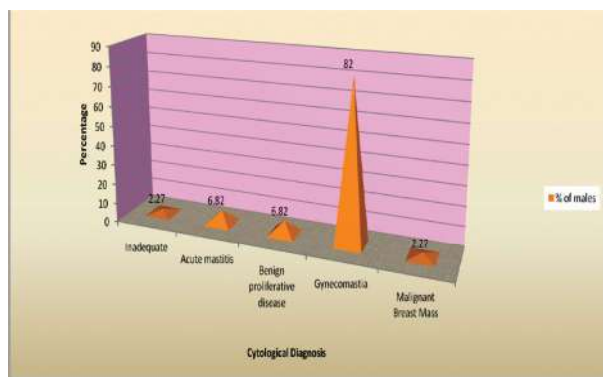


Fig. 2: Cytological diagnosis in males

In females, fibroadenoma showed the highest (46.06%) incidence followed by carcinoma (17.21%), fibroadenomatoid hyperplasia (8.09%) and acute mastitis (7.05%) cases. Among the inflammatory lesions, there were 0.62%, 7.05%, 0.41%, 0.28%, 0.28%, and 2.9% lesions of acute suppurative mastitis, acute mastitis, non-tuberculous granulomatous mastitis, duct ectasia, tuberculous mastitis, and fat necrosis, respectively. (Fig. 3)

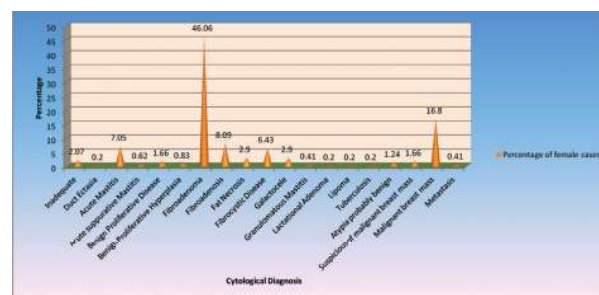


Fig. 3: Cytological diagnosis in females

Out of 526 FNAC cases, 173 were correlated in histology. Remaining were not correlated in histology because they lost to follow-up for further management.

In males, all FNAC diagnosis showed 100% correlation on histopathology. (Table 1).

Table 1: Histopathological diagnosis of various cytological diagnosis in male cases

Cytological diagnosis	Histopathological diagnosis		Total
	Gynecomastia	IDC	
C2 Gynecomastia	21	0	21
C5 Malignant breast mass	0	1	1
			22

In females on histopathological examination, (Table 2).

Out of 113 C2 FNAC diagnosis, 4 cases were diagnosed as ductal carcinoma NOS (4 false negatives)

Both 2 cases of C3 category came out to be benign.

All 3 C4 FNAC diagnosis were diagnosed as benign lesions. (3 false positive).

Out of 32 cases of cytologically diagnosed C4 lesions, all came out to be malignant lesions. (Table 3).

So, in total there were 3 false positive cases and 4 false negative cases in this study. (Table 4).

Following histopathologic correlation with FNA, we calculated the sensitivity, specificity, positive and negative predictive values, positive and negative likelihood ratio, disease prevalence and accuracy. (Table 5).

**Table 2:** Histopathological diagnosis of benign smears in female cases

Categories	Cytological Diagnosis	Histopathological Diagnosis									Total	
		Galactocele	Acute mastitis	Fibrocystic disease	Fibroadenomatoid hyperplasia	Juvenile fibroadenoma	Fibroadenoma	Tubular adenoma	Benign Phylloides Tumor	hyperplasia		Ductal carcinoma (NOS)
C2	Acute Suppurative mastitis	0	1	0	0	0	0	0	0	0	0	1
	Benign Proliferative Disease	0	0	0	0	0	0	0	0	1	0	1
	Benign Proliferative Lesion	0	0	0	0	0	0	0	4	0	0	4
	Fibro-adenoma	0	0	2	3	1	82	2	1	0	3(FN)	93
	Fibro-adenomatoid Hyperplasia	0	0	0	2	0	2	0	0	0	0	4
	Fat necrosis	0	0	0	0	0	0	0	0	0	1(FN)	1
	Fibrocystic Disease	0	0	5	0	0	1	0	0	0	0	6
	Galactocele	1	0	1	0	0	0	0	0	0	0	2
C3	Atypia probably benign	0	0	0	0	0	2	0	0	0	0	2

**Table 3:** Histopathological diagnosis of suspicious and malignant smears in female cases

Categories	Cytological Diagnosis	Histopathological Diagnosis						Total	
		Acute mastitis	Fat necrosis	Fibrocystic disease	Ductal carcinoma NOS	Medullary carcinoma	Lobular carcinoma		Metastatic adenocarcinoma
C4	Suspicious of Malignant breast mass	1(FP)	1(FP)	1(FP)	0	0	0	0	3
C5	Malignant breast mass	0	0	0	28	1	3	0	32
	Metastasis	0	0	0	0	0	0	1	1

**Table 4:** Cyto-histopathological correlation of breast lesions in present study.

FNAC Result	Histopathological Diagnosis	
	Benign	Malignant
C2+C3(Benign)	132(T.N.)	4(F.N.)
C4+C5(Malignant)	3(F.P.)	34(T.P.)
Total	134	39

**Table 5:** The diagnostic accuracy of FNAC in histologically correlated cases.

Sensitivity	89.47%
Specificity	97.78%
Positive likelihood ratio	40.26

Negative likelihood ratio	0.11
Disease prevalence	21.97%
Positive predictive value	91.89%
Negative predictive value	97.06%
Accuracy	95.95%

## Discussion

Breast cancer is one of the common clinical problems in India. Although there has been little success in preventing breast cancer, significant reduction of mortality could be achieved by early detection. Early diagnosis also helps to prevent patients discomfort and anxiety [14,15]. It is

the general consensus that a firm pre-operative diagnosis should be established before surgery, and FNAC is an extremely useful diagnostic technique. It has already been established that FNAC is an easily performed outpatient diagnostic method for determining the nature of breast lesion. Its success is due to its diagnostic accuracy and its cost effectiveness in the management of breast lump. As a diagnostic modality, FNA cytology has many advantages for the patients as well as for the physicians. Before the introduction of FNAC, open biopsy/true cut biopsy was carried out in only suspicious cases.

The present series confirms the accuracy and clinical utility of fine needle aspiration cytology in the investigation of the patient with benign and malignant breast disease. The accuracy of the diagnosis in patients with malignant breast disease is in the range of 85 to 90% in most of the series.

The rate of inadequate smears in various studies ranged from 1.92% to 20% [16,17,18,19]. In the present study there were 2.09% (11 cases) cases categorised as C1 (inadequate) which is on the lower side of the range. Smears showing scant cellularity and haemorrhagic aspirate were included in C1 (inadequate) category. Park IA et al. [20] observed that, the success of cytodiagnosis varied according to histologic subtypes such as, FNAC tend to be inadequate and false negative in case of duct carcinoma of schirrous subtype. Other, main cause for inadequate smears is lack of technical experience in performing FNA, preparation, and fixation of smears. Also, FNA of ill-defined mass or lesions with hyalinization and deeply situated lumps may contribute to the inconclusive diagnosis. Higher inadequacy rate reduces the sensitivity of cytology. Inadequacy can be reduced by repeating the procedure twice. These cases require re-evaluation of clinical and radiological findings as well as adequate follow-up, mostly in cases of palpable breast abnormalities.

The rate of benign cases in various studies range from 60.2 to 74.76% [17,19,21]. Our study reported 80.41% (423 cases) in C2 (benign) category which is comparable to other studies.

In females among the type of benign cytological diagnosis, fibroadenoma showed the highest (46.06%) incidence followed by, fibroadenomatoid hyperplasia (8.09%) and acute mastitis (7.05%) cases.

The rate of fibroadenoma cases reported in various studies ranged from 8 to 38.3% [19,22,23,24,25,26]. The higher rate in our study was perhaps caused by

increased awareness among young women about the breast lump.

On cytology, among the inflammatory lesions, there were 0.62%, 7.05%, 0.41%, 0.28%, 0.28%, and 2.9% lesions of acute suppurative mastitis, acute mastitis, Non-tuberculous granulomatous mastitis, duct ectasia, tuberculous mastitis, and fat necrosis, respectively. The results in our study were less than the range in various studies [19,23,27].

There were 2.90% galactocele cases (14 cases), which revealed milk during aspiration and microscopically histiocyte in the background of milk.

Regarding fibrocystic disease of breast, we found 31 (6.43% of female FNAC) cases in this study. The rate of Fibrocystic disease reported in various studies ranged from 21 to 49% [19,23,24]. The rate in our study is much lower than the above-mentioned studies as fibrocystic disease presents with ill-defined mass with no pain or less complaints and female may feel reluctant to seek consultation for this type of lesion.

A total number of 6 (1.14%) cases of C3 (atypia probably benign) category were found. 51 (3.3%) atypical cases were noted by Yeoh and Chan [28]. Cytologic atypia comprises nuclear pleomorphism, loss of cohesiveness, irregular nuclear contours, irregular chromatin pattern, hyperchromasia, and high nuclear/cytoplasmic ratio. Architectural atypia corresponds to cribriform clusters, overlapping, and crowding [29]. For practical purposes, ADH and low-grade DCIS (ductal carcinoma in situ) are better categorized as proliferative breast disease with atypia/borderline lesions since all of these lesions will require excisional biopsy [30].

We reported 1.52% cases in C4 (suspicious for malignant cells) category, which is comparable to various other studies [22,24,31]. They needed core biopsy for confirmation of malignancy.

The percentage of C5 (malignant) cases in our study were 15.97% which is near to most of the studies [16,17,22,24,25,31]. Out of 32 cases of cytologically diagnosed malignant lesions, infiltrating ductal carcinoma was the most common histopathological diagnosis (28 cases). 1 case was diagnosed as medullary cancer. There was 1 case reported as lobular carcinoma in our study. Mainly diagnosed on histopathology, whereas cytology was able to explain the presence of malignancy only. Lobular carcinoma cannot be consistently differentiated from ductal carcinoma by cytology [32].

Total 40 male patients visited cytology OPD with

complains of breast lump. Out of 40, 4 patients had bilateral breast lumps. So, total 44 FNAC cases were evaluated. Out of 44 FNAC cases, 36 were reported as gynecomastia which is the most common male breast lesion as per literature too [33,34]. One case was reported as IDC-NOS which is 1.2% of total malignant cases in our study. Incidence of male breast cancer is less than 1%. Our incidence rate is slightly higher. Out of 44 cases, 22 cases were available for histopathological examination. 21 cases of gynecomastia and 1 case of malignancy. Diagnostic accuracy for gynecomastia and malignancy in males was 100%.

Anuradha Joshi et al. [35] has noted 13.8% cases of carcinoma and 58% cases of benign breast lesions amongst males and a sensitivity, specificity and diagnostic accuracy of 100% for male breast lesions. In the present study there were 2.27% cases of carcinoma and 95.45% cases of benign breast lesions amongst males and a sensitivity, specificity and diagnostic accuracy of 100% for male breast lesions.

Out of 526 FNAC cases, 173 were correlated in histology.

In the present study we noted 4 false negative cases. Although this can be regarded as a sampling error, the effect on management could be obvious. False negative rate in our series is 10.52%, which is comparable to various other series, which quoted false negative rate of 1 to 31% with average range of 10% [36]. There are some limitations to FNAC procedure, for example, a malignant lesion smaller than 1 cm may be missed during aspiration resulting in false negative results. Lack of cellular pleomorphism often gives false negative diagnosis. Some studies suggest criteria for adequacy during cytology reporting if cut off to 6 epithelial cell clusters reduces the false negative rates by approximately 50% [37].

In the present study we found 3 false positive cases which were cytologically diagnosed as suspicious of malignancy, and turned out to be cases of acute mastitis, fat necrosis and fibrocystic disease. The false positive rate was 2.22%, which was within the range of 0 to 10% seen in various other series [10,12,36,38]. False positive diagnosis is always interpretation errors. They are highly undesirable, but in large volume institutions, they will occur from time to time in the process of evaluation of rare lesion, diagnostic pitfalls and look alike such as some fibroadenomas with myoepithelial hyperplasia, complex sclerosing lesions and sclerosing adenosis. False positive diagnosis should be avoided because mastectomy or other treatments may in certain centres be

performed based entirely on FNA cytologic findings.

The sensitivity of test means the ability of a test to identify correctly all those who have the disease (true positive) which in the present study stands for the malignant diagnoses. The sensitivity in various series ranged between 89.5% to 100% [21,38,39]. The sensitivity in our study came out to be 89.47% which was comparable to other studies.

The specificity of test means the ability of a test to identify correctly those who do not have the disease (true negative) which in the present study stands for benign diagnoses. Specificity in various studies ranged from 92.5% to 98% [19,21,38,39]. Our study reported specificity of 97.78% which was comparable to other studies. Feoli F et al. noted that specificity can be improved with increased experience, detailed evaluation of nuclear atypia, use of Papanicolaou-stained material and with accurate selection of patients [40].

The Positive and negative predictive value of present study were 91.89% and 97.06% respectively, which was comparable to other studies [19,21,38,39].

Efficiency of 95.95% was also comparable to all the series mentioned above [19,21,38,39].

The reasons for such a large range of variable results are multifactorial and the main factors being the small number of cases of FNA, published lack of onsite service, and coordination between surgeons, radiologists and pathologists.

Thus, in the present given study the sensitivity, specificity, positive predictive value, negative predictive value and efficiency of malignant cases is 89.47%, 97.78%, 91.89%, 97.06% and 95.95% respectively.

The high specificity and predictive value of positive results allow for the early diagnosis, treatment and management of breast cancer [41,42,43].

## Conclusion

Fine-needle aspiration cytology can reasonably subclassify most of the benign and malignant breast lesions but there is still a challenge with some cases of mastitis, fat necrosis, fibrocystic disease, lobular carcinoma and medullary carcinoma.

A high sensitivity and a high positive predictive value proved that a positive FNAC in the breast means a definite diagnosis of the concerned pathology when compared with the final histology report. The high specificity and a high negative

predictive value for malignancy illustrated the high accuracy of FNAC in the diagnosis of malignancy in the breast.

It can be concluded that, FNAC can be used as a preliminary investigation for breast lump and when performed by an expert pathologist, the diagnostic accuracy of FNAC is very high. However, before going for definitive treatment, open biopsies are necessary as there have been false negative results for FNAC.

## References

1. Cochrane RA, Singhal H, Monypenny IJ, Webster DJ, Lyons K, Mansel RE. Evaluation of general practitioner referral to a specialist breast clinic according to the U K national guidelines. *Eur J Surg Oncol.* 1997;23:198-201.
2. Parkin DM, Bray F, Ferlay J, Pisani P. Estimating the world cancer burden: Globocan 2000. *Int J Cancer.* 2001;94:153-6.
3. Sandhu DS, Sandhu S, Karwasra RK, Marwah S. Profile of breast cancer patients at a tertiary care hospital in north India. *Indian J Cancer.* 2010;47:16-22.
4. Rubin M, Horiuchi K, Joy N, Haun W, Read R, Ratzler E et al. Use of fine needle aspiration for solid breast lesions is accurate and cost-effective. *Am JSurg.* 1997;174:694-8.
5. A. Berner, E. Sigstad, W. Reed, and B. Risberg. Fine-needle aspiration cytology or core biopsy when diagnosing tumours of the breast. *Tidsskrift for den Norske Laegeforening.* 2003;123:1677-9.
6. D. Lieu. Value of cytopathologist-performed ultrasound guided fine-needle aspiration as a screening test for ultrasound-guided core-needle biopsy in nonpalpable breast masses. *Diagnostic Cytopathology.* 2009;37:262-9.
7. T. Ishikawa, Y. Hamaguchi, M. Tanabe, Momiyama N, Chishima T, Nakatani Y et al. False-positive and false-negative cases of fine-needle aspiration cytology for palpable breast lesions. *Breast Cancer* 2007;14:388-92.
8. Martin HE, Ellis EB. Biopsy by needle puncture and aspiration. *Ann Surg.* 1930;92:169-81.
9. Rimm DL, Stastny JF, Rimm EB, Ayer S, Frable WJ. Comparison of the costs of fine needle aspiration and open surgical biopsy as methods for obtaining a pathologic diagnosis. *Cancer.* 1997;81:51-56.
10. Silverman JF, Lamm DR, O'Brien K, Norris HT. The triage role of fine needle aspiration biopsy of palpable breast masses. *Diagnostic accuracy and cost effectiveness.* *Acta Cytol.* 1987;31:731-6.
11. Zarbo RJ, Howanitz PJ, Bachner P. Interinstitutional comparison of performance in breast fine needle aspiration cytology. *Arch Pathol Lab Med.* 1991; 115:743-50.
12. Bell D.A., Hajdu S.I., Urban J.A. and Gaston J.P. Role of aspiration cytology in the diagnosis and management of mammary lesions in office practice. *Cancer.* 1983;51:1182-9.
13. [No authors listed]. – The uniform approach to breast fine-needle aspiration biopsy. National Cancer Institute Fine-Needle Aspiration of Breast Workshop Sub committees. *Diagn Cytopathol.* 1997;16(4):295-311.
14. Hughes JE, Royle GT, Buchanan R, Taylor I. Depression and social stress among patients with benign breast lesion. *Br J Surg.* 1986;73:997-9.
15. Ellman R, Angeli N, Moss S, Chamberlain J, Maguire P. Psychiatric morbidity associated with screening of breast cancer. *Br J Cancer.* 1989;60:781-4.
16. Shrestha A, Chalise S, Karki S and Shakya G. Fine needle aspiration cytology in a palpable breast lesion. *Journal of Pathology of Nepal.* 2011;1:131-135.
17. Feichter EG, Haberthur F, Gobat S, Dalquen P. Breast cytology statistical analysis and cytohistologic correlation. *Acta Cyto.* 1997;41:327-32.
18. Hitchcock A, Hunt CM, Locker A, Koslowski J, Strudwick S, et al. A one-year audit of fine needle aspiration cytology for the pre-operative diagnosis of breast disease. *Cytopathology.* 1991;2:167-76.
19. Bukhari MH, Arshad M, Jamal S, Niazia S, Bashir S, Bakhshi IM et al. Use of fine needle aspiration cytology in the evaluation of breast lumps. *Pathology Research International.* 2011;01:01-10.
20. Park IA, and Ham EK. Fine needle aspiration cytology of palpable breast lesion; histologic subtypes in false negative cases. *Acta Cytologica.* 1997;41(4):1131-7.
21. Rocha PD, Nadkarni NS and Menzes S. Fine needle aspiration biopsy of breast lesion and histopathologic correlation. *Acta Cytologica.* 1997; 41:705-12.
22. Ahmed HG, Ali AS, Almobarak AO. Utility of fine-needle aspiration as a diagnostic technique in breast lumps. *Diagn Cytopathol.* 2009;37:881-4.
23. Kumar R. A clinicopathologic study of breast lumps in Bhairahwa, Nepal. *Asian Pac J Cancer Prev.* 2010; 11:855-8.
24. Pradhan M, Dhakal HP. Study of breast lump of 2246 cases by fine needle aspiration. *JNMA J Nepal Med Assoc.* 2008;47:205-9.
25. Mayun AA, Pindiga UH, Babayo UD. Pattern of histopathological diagnosis of breast lesions in Gombe, Nigeria. *Niger J Med.* 2008;17:159-62.
26. Rahman MZ, Sikder AM, Nabi SR. Diagnosis of breast lump by fine needle aspiration cytology and mammography. *Mymensingh Med J.* 2011;20:658-64.

27. Nemenqani D, Yaqoob N. Fine needle aspiration cytology of inflammatory breast lesions. *J Pak Med Assoc.* 2009;59:167-70.
  28. Yeoh GP, Chan KW. Fine needle aspiration of breast masses: an analysis of 1533 cases in private practice. *Hong Kong Med J.* 1998;4:283-8.
  29. Barbara S. Ducatman, Helen H. Wang. Breast. In: Edmund S. Cibas, Barbara S. Ducatman, 3rd edition. Philadelphia, Saunders Elsevier, 2009. pp.221-254.
  30. Ellis OI, Schnitt SJ, Sastre-Garau X. Invasive breast carcinoma. In: Tavassoli FA, Devillee P (eds) *Pathology and Genetics of Tumours of the Breast and Female Genital Organs.* IARC Press, Lyon. 2003.
  31. Yip CH, Jayaram G, Alhady SF. The experience with fine needle aspiration cytology in the management of palpable breast lumps in the University Hospital Kuala Lumpur. *Med J Malaysia.* 2000;55:363-7.
  32. Johnson et al. Breast fine needle aspiration cytology and core biopsy: a guide for practice. *Cancer.* 2003; 19:203-08.
  33. Lilleng R, Paksoy N, Vural G, Langmark F and Hagmar B. Assessment of FNAC and Histopathology for diagnosing Male Breast Masses. *Acta cytol.* 1995;39:887-81.
  34. Amrikachi M, Green LK, Rone R and Ramzi I. Gynaecomastia: Cytological Features and Diagnostic Pitfalls in Fine Needle Aspirates. *Acta Cytologica.* 2001;45:948-52.
  35. Joshi A, Kapila K, Verma K. Fine needle aspiration cytology in the management of male breast masses. *Acta Cytologica.* 1999;43(2):334-8.
  36. Silverberg DelvillisFrable. *Principle in Practice and Surgical Pathology and Cytopathology,* Singapore, Churchill Livingstone 1997, 3rd edition volume; 578-84.
  37. Abele JS, Wagner LT, Miller TR. Fine needle aspiration of the breast: cell counts as an illusion of adequacy. *Cancer cytopathology.* 1998;84:321-3.
  38. Dominguez F, Riera JR, Tojo S and Junco P. Fine needle aspiration of breast masses, an analysis of 1398 patients in a community hospital. *Acta cytological.* 1997;41:341-7.
  39. Kline TS, Joshi LP, Hunter SN. Fine needle aspiration of the breast: diagnoses and pitfalls. *Cancer.* 1979; 44:1458-64.
  40. Feoli F, Paesmans M, Van Eeckhout P. Fine needle aspiration cytology of the breast: Impact of experience on accuracy, using standardized cytologic criteria. *Acta Cytologica.* 2008;52:145-51.
  41. Nggada HA, Tahir MB, Musa AB, Gali BM, Mayun AA, Pindiga UH. Correlation between histopathologic and fine needle aspiration cytology diagnosis of palpable breast lesions: a five-year review. *Afr J med sci.* 2007;36:295-8.
  42. Purasiri P, Abdalla M, Heys SD, Ah-See AK, McKean ME, Gilbert FJ et al. A novel diagnostic index for use in the breast clinic. *J R Coll Surg Edinb.* 1996;41:30-4.
  43. Kaufman Z, Shpitz B, Shapiro M, Rona R, Lew S, Dinbar A. Triple approach in the diagnosis of dominant breast masses: combined physical examination, mammography and fine needle aspiration. *J Surg Oncol.* 1994;56:254-7.
-